


547 • *Carassius auratus* 'Goldfish'

Bacterial + Parasitic + Fungal: Goldfish with *Ichthyobodo* and also Columnaris Disease and Fungal infection on caudal area.




548 • *Cyprinus carpio* 'Koi'

Bacterial infection: Koi with many small white patches spread out over body caused by Columnaris Disease. (Photo M. Lammens)



549 • *Cyprinus carpio* 'Koi'

Bacterial infection: Koi (see ill. 548) with small specks caused by Bacterial (*Flavobacterium*) infection. (Photo M. Lammens)



550 • *Cyprinus carpio* 'Koi'

Bacterial infection: Koi (see ill. 548+549) after removal of gill cover with necrotic gills caused by Columnaris. (Photo M. Lammens)

c. Swollen belly/Dropsy: see p. 148 (Ill. 551-558)

Cause: usually *Pseudomonas fluorescens*

This disease occurs among fish that are weakened by stress, contamination, age or occasionally also after a skin or gill flukes infection.

Attention: bloated abdomens must not be mistaken for deformities with abdominal lumps (see below)

Clinical presentation: The fish have a swollen belly, usually with raised or protruding scales, sometimes with bleeding patches or skin lesions, or ulcers (see above).

The fish are listless, lie on the bottom and no longer eat.

Treatment: Excessively swollen fish cannot be saved, but no time should be lost in treating the other fish in the pond or aquarium with Nifurpirinol or antibiotics.

Make sure to determine the exact cause of the disease.



551 • *Carassius auratus* 'Yellow Goldfish'

Bacterial infection: Yellow Goldfish with swollen abdomen with bloody patch: Dropsy (Bacterial infection).

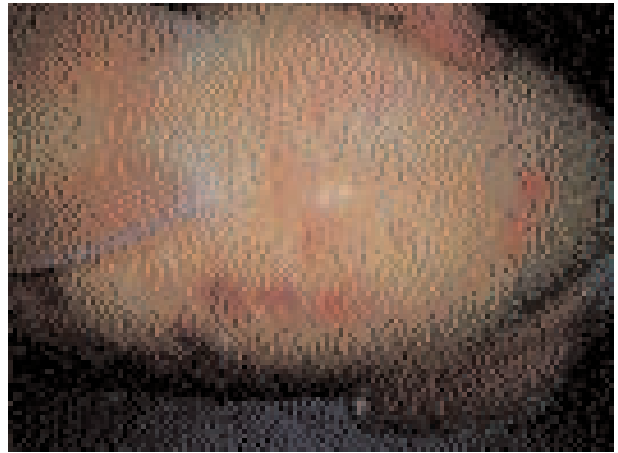

552 • *Carassius auratus* 'Yellow Goldfish'

Bacterial infection: Yellow Goldfish (see ill. 551) with raised scales and red streaks in fins: Dropsy.



553 • *Cyprinus carpio* 'Koi'
Bacterial infection: Koi with Dropsy (and also raised scales) caused by Bacterial infection. (Photo M.Lammens)



554 • *Cyprinus carpio* 'Koi'
Bacterial infection: Koi (see ill. 553) with red small patches on the abdomen caused by Dropsy. (Photo M.Lammens)



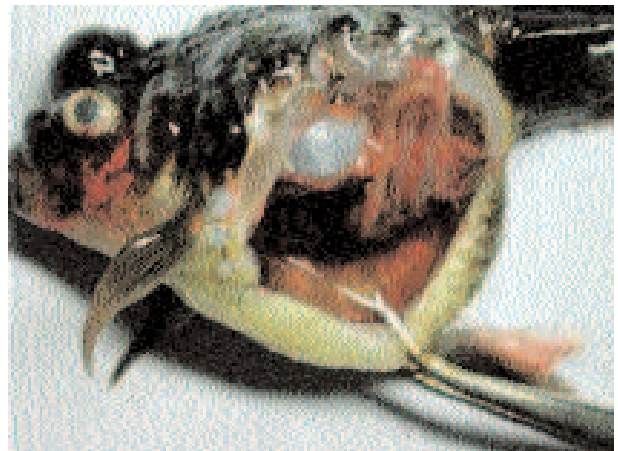555 • *Carassius* 'Oranda Ranchu'
Bacterial infection: Oranda Ranchu with Dropsy and typical raised scales caused by Bacterial infection.



556 • *Carassius* 'Oranda Ranchu'
Bacterial infection: Oranda Ranchu (see ill. 555) with raised scales and red patch at anus caused by Bacterial Dropsy.



557 • *Carassius* 'Oranda Pearlscale'
Bacterial infection: Oranda Pearlscale with Dropsy and red patch caused by Bacterial infection.



558 • *Carassius* 'Oranda Pearlscale'
Bacterial infection: Dissected Pearlscale (see ill. 557) with copious fluid in abdomen (Ascites) caused by Dropsy.

d. FishMycobacterium (FishMB): see p. 152 (III. 559)

Cause: *Mycobacterium* sp.


Clinical presentation: occasionally occurs in cultured (especially old) goldfish and koi.

The fish lose their colour, become listless and emaciated. Ulcers and frayed, damaged fins may develop, sometimes accompanied by exophthalmos or protruding eyes.

Treatment: only possible in the initial stage of the infection with Tetracycline or Erythromycine. Advanced infections can no longer be treated, so it is recommended to euthanase the dying fish.



Tip: In case of ulcers or skin necrosis it is recommended to take immediate action and, if necessary, to have a fish doctor carry out an examination to determine the actual cause and therefore also the appropriate treatment.



559 • *Carassius auratus* 'Yellow Goldfish'

Bacterial + Fungal inf.: Yellow Goldfish: Bacterial wound (FishMB) + Fungal infection + black pigmentation patches.

4. UNICELLULAR PARASITIC INFECTIONS: (III. 560-571)

In the case of ornamental fish these are mainly parasites on skin and gills.

a. *Ichthyobodo* (formerly *Costia*): see p. 158
(III. 560-567)

Mainly occurs in ponds at temperatures of 12°C or higher, usually among fish living in dirty water, that have become weak and therefore have a malfunctioning immune system.

Clinical presentation: Turbidity of the skin, in many cases rather quickly followed by secondary bacterial and/or fungal infections that conceal the actual disease (here: *Ichthyobodo*). The fish clamp their fins or the fins are held close to the body.

The fish lie listless on the bottom and may shoot away. The fish may also wobble. The disease can result in high mortality.

Treatment: first of all test the water quality!

- Short bath: baths at 30°C for 1 hour with plenty of air or with 20-50ml/100 l of Formalin for 30-60 minutes
- Long bath: 10ml/m³ of FMC to be repeated after 1 week; or 25ml/1 m³ of Formalin to be repeated after 2 days!


Preferably administer Nifurpirinol at the same time as treatment against secondary bacterial infections.

ATTENTION: Do NOT use Formalin or FMC at temperatures lower than 12-13°C.




560 • *Carassius* 'Black Moor'

Parasitic infection: Black Moor with severe turbidity of the skin caused by massive Skin Fluke (*Gyrodactylus*) infection.



561 • *Carassius 'Black Moor'*

Parasitic infection: Black Moor with Turbidity of the skin caused by Skinflukes with secondary Bacterial infection.



562 • *Carassius 'Oranda Redcap'*

Parasitic infection: Oranda Redcap with hardly noticeable turbidity of the skin caused by parasitic *Ichthyobodo* infection.




563 • *Carassius 'Calico Oranda'*

Parasitic infection: Calico Oranda with turbidity and patches on skin caused by *Ichthyobodo* infection.



564 • *Carassius auratus 'Yellow Goldfish'*

Parasitic + Bacterial infection: Exhausted Yellow Goldfish with *Ichthyobodo* and Bacterial infection.



565 • *Carassius auratus 'Goldfish'*

Parasitic + Bacterial infection: Goldfish with *Ichthyobodo* and secondary Bacterial infection with wound and finrot.



566 • *Carassius 'Oranda Panda'*

Parasitic + Bacterial inf.: Panda Goldfish with turbidity of skin and eyes caused by *Ichthyobodo* and Bacterial (finrot) infection.

b. *Trichodina*: see p. 167 (Ill. 567)

It is not uncommon for a small number of *Trichodina* to appear on the skin and/or gills of pond fish without causing disease.

If a large number of them are present, however, they cause a chronic mortality of 1%, with the secondary bacterial and/or fungal infections leading to further and greater losses. This parasite is sometimes introduced into the pond by fish or plants from the wild.

Clinical presentation: see bacterial or fungal infections. The fish occasionally scrape over the bottom or against objects.

Treatment: first test the water quality and then treat, if necessary, with Formalin or FMC (see above, *Ichthyobodo*).

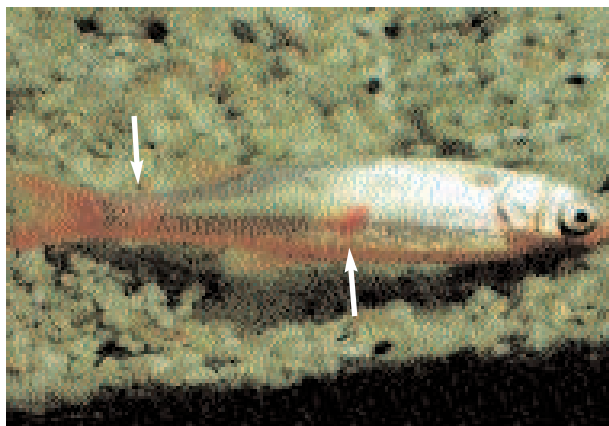
However, cases of *Trichodina* that are immune to FMC treatments have also been reported.

Another possible treatment, but one that is not recommended for the plants and snails, is to introduce 0.2mg/l of Copper Sulphate into the pond for a period of 3 weeks.

If we can remove the fish, they can be treated 3 to 4 times with 0.25 ml/l of Formalin for 10 minutes (once a week). Treatments with Trichlorfon (poisonous for Orfe Rudd/Rock Bass and Tench!) have also been helpful. If possible keep the fish in the dark during the treatment.



Tip: With the majority of parasitic infections only the secondary bacterial infections can actually be seen, which explains why most fish amateurs treat the fish only against bacteria, so that the treatment will not be effective.



567 • *Leuciscus idus* 'Golden Orfe'

Parasitic + Bacterial infection: Golden Orfe with several wounds and turbidity of skin caused by *Trichodina* and Bacterial infection.

c. *Chilodonella*: see p. 163 (Ill. 568)

Mainly occurs in the gills, but also on the skin, and usually as a result of overcrowding or contaminated water.

Is believed to be one of the most dangerous diseases.


Clinical presentation: The fish show turbidity of the skin and have severe breathing problems. They are listless, apparently dead, lie on the bottom or hang at the surface and have an open gill cover. This infection can cause mass mortality.

Treatment: see *Ichthyobodo/Costia*




568 • *Carassius* 'Oranda Calico'

Parasitic infection: Calico Fantail with turbidity of skin caused by *Chilodonella* infection in gills and on head.



569 • *Carassius 'Oranda Pearlscale'*
Parasitic infection: Pearlscale with infection caused by Whitespot (*Ichthyophthirius*).



570 • *Carassius 'Oranda Pearlscale'*
Parasitic infection: Close-up of Pearlscale (see ill. 569) with large Whitespots (*Ichthyophthirius*) on tail.

d. *Ichthyophthirius* (Whitespot/ICH): see p. 173 (Ill. 569-570)

This infection appears mainly during the hot season but also at low temperatures (in which case the parasite's cycle can last more than 10 days).

Clinical presentation: The fish have breathing difficulties (the spots are also present in the gills), which causes them to hang at the surface near the water inlet or to lie listlessly as a group on the bottom or near the filter inlet or outlet. The fish may also wobble or scrape over the bottom or against objects. The fins may be held close to the body and the fish may swim irregularly and race through the water.

Attention: Sexually mature male Goldfish may by nature display white specks around the head region and on the pectoral fins. These must not be mistaken for Whitespot.

Treatment: preferably with Malachite green: 0.1-0.2 gm/m³, to be repeated twice after 3-day intervals. At temperatures lower than 15°C, repeat after 5-day intervals. A water change may prove necessary. Treatments with FMC can also yield good results.

ATTENTION: Malachite green can be poisonous. It is useful to administer Nifurpirinol at the same as a treatment against secondary bacterial infections.

- In a **pond with plants:** treat with Formalin every 2 days, and repeat 3 times.
 - In a **pond without plants:** treat with Copper Sulphate for a period of 6 weeks; especially for cold ponds (<15°C), repeat Copper Sulphate treatment every day.
- At temperatures between 20 to 25°C, treat every 2 days and repeat at least 3 times.
 Low temperatures will increase the life cycle of the spot.

e. *Hexamita/Spiroucleus*: see p. 169 (Ill. 571)

Frequently occurs in very young Koi and small Goldfish. This infection involves a high mortality rate. Rarely occurs in older fish.

Could possibly be transmitted by amphibians.

Clinical presentation: the fish lose weight and also become listless. They slowly lose their appetite. The faeces may be long, slimy strings hanging from the anus.

The first sick fish isolate themselves from the group.

Treatment: Metronidazole: in the feed and/or water. The treatment may have to be repeated after 7-14 days.



571 • *Cyprinus carpio 'Koi'*
Parasitic infection: Skinny Koi with *Spiroucleus* infection and with damaged kidney.

f. *Stalked ciliates*: (False Fungal Infection)
see p. 167

Occasionally occurs on the skin, fins and sometimes in the gills.

Usually in contaminated ponds/tanks.

Clinical presentation: the fish exhibit small cotton-like growths that cannot be treated with an anti-fungal drug.

Treatment: see p. 169

g. *Cryptobia* species: see p. 162

The most common is *Cryptobia branchialis*, a parasite that occurs in the gills.

Clinical presentation: The fish scrape their gill cover against objects or over the bottom, the skin colour darkens, the fish look emaciated and are also prone to secondary bacterial infection.

Treatment: with Formalin or FMC (an anti-bacterial drug may also prove necessary)

h. *Piscinoodinium*: or Velvet Disease: see p. 177

This parasite very rarely occurs in Goldfish and is seldom encountered in Koi.

5. Multicellular parasitic infections:
(III. 572-582)

Mainly skin and gill flukes

a. *Gyrodactylus*: Skin Flukes: see p. 184
(III. 572-575)

This parasitic worm quickly reproduces itself on the skin because it is livebearing and the young worms (up to 3 at a time) are born from the adult worms on the skin. It may also be found in the gills.

The worm can readily be identified in a skin scraping under the microscope.


The lower the temperature the slower the skin flukes will develop and reproduce itself.

Clinical presentation: Usually there is excess slime formation on the skin, the fish scrape over the bottom or against objects, red patches or lesions can be observed, with secondary bacterial infection after damage by the skin flukes. If the skin flukes has also infected the gills, the gill covers will be flared open and the fish will be breathing rapidly.

Treatment: see p. 186

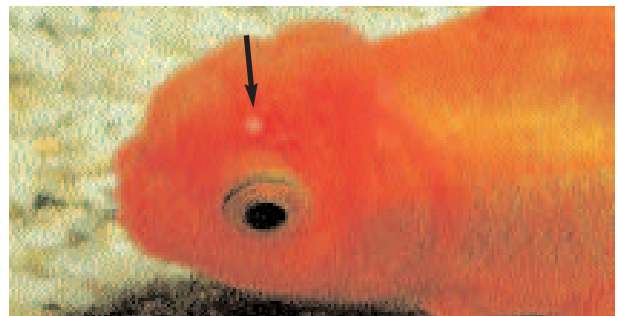


Tip: Skin Flukes and Gill Flukes are usually accompanied by bleeding patches on the skin, caused by damage or by a bacterial infection, so that this parasitic infection cannot be recognised.




572 • *Carassius auratus* 'Sarassa'

Parasitic + Bacterial infection: Sarassa with many Skinflukes and patches on skin and tailrot (Bacterial infection).



573 • *Carassius* 'Red Oranda'

Parasitic infection: Red Oranda with small white spots on head caused by Skinflukes (*Gyrodactylus*).



574 • *Carassius* 'Red Oranda'

Parasitic infection: Red Oranda with a crater in the head = damage caused by Skinflukes (*Gyrodactylus*).



575 • *Carassius auratus* 'Goldfish'

Parasitic + Bacterial infection: Goldfish with ulcer caused by Skinfluke (*Gyrodactylus*) and Bacterial infection.

b. *Dactylogyrus*: Gill Flukes: see p. 186
(Ill. 576-582)

This parasite mainly occurs in the gills, but also on the head and on the skin.

Reproduction occurs by means of eggs that develop on the bottom (or in the filter), so that the entire pond (and its filter) will have to be treated. If the water is cold, the larvae do not emerge from the eggs until several weeks or months have passed! This should be taken into account in the spring when the water warms up and the gill flukes may appear.

These parasites (usually 1 mm) can easily be identified by examining a skin or gill scraping of a koi or goldfish under the microscope.

Clinical presentation: The fish scrape over the bottom or against objects, they are emaciated, breathe rapidly and have a flared open gill cover.

A small number of parasites may be present on the fish without causing any damage. Only large numbers of them will actually cause an infection.

The worms usually cause damage, which in turn leads to secondary bacterial infections that will kill the fish.

Treatment: see p. 186

c. Other worms rarely occur in coldwater ornamental fish.

They do, however, occur in wild-caught fish or in species that are bred in natural ponds.

Bloodsuckers, too, are usually found on wild-caught fish: treatment consists in removing the parasite or administering Trichlorfon



577 • *Carassius 'Redcap Oranda'*

Parasitic + Bacterial infection: Very skinny Redcap with Gillflukes and red small patches (beginning of Bacterial infection.)




578 • *Carassius 'Bubble Oranda Eye'*

Parasitic infection: Irregular-swimming Bubble Eye with respiratory problems + extended gillcovers caused by Gillfluke infection.




576 • *Carassius auratus 'Goldfish'*

Parasitic infection: Emaciated Goldfish with Gillfluke (*Dactylogyrus*) infection.




579 • *Carassius 'Oranda Lionhead'*

Parasitic + Bacterial infection: Lionhead with Gillfluke infection and bleeding under skin caused by Bacterial infection.




580 • *Cyprinus carpio* 'Koi'

Parasitic + Bacterial infection: Koi with severe Gillfluke infection also affecting head with secondary Bacterial infection.




581 • *Cyprinus carpio* 'Koi'

Parasitic infection: Koi (ill. 580) with extended gill cover caused by infection with Gillflukes (*Dactylogyrus*).



582 • *Cyprinus carpio* 'Koi'

Parasitic + Bacterial infection: Koi (ill. 580): sunken eyes, extra mucus on head, damaged gill cover: Gillfluke infection.



583 • *Carassius auratus* 'Goldfish'

Parasitic infection: Goldfish with 2 Anchorworms (*Lernaea*) with eggsacs, attached to the skin at base of dorsal fin.

6. PARASITIC LICE AND ANCHORWORMS: (Ill. 583-584)



Tip: Lice or Anchorworms may be introduced by live fish food or wild plants.

a. *Argulus* or Carp Louse: see p. 197

Is clearly recognisable (up to 13 mm in size) and frequently occurs in pond fish and Koi, usually during the summer months when the parasite can quickly reproduce itself.

The Lice can kill smaller fish and cause wounds and consequently bacterial infections in larger fish.

Treatment: see p. 199

If only a few parasites are present, they can be removed by hand (or with tweezers).

b. *Lernaea* or Anchorworm: see p. 199 (583-584)

Can easily be recognised (up to 20 mm in size) and usually occurs en masse in ponds during the summer months. They usually cause lesions, ulcers and secondary Fungal infection.

Treatment: see p. 200

The dead Anchorworms will not drop from the fish until after a number of weeks/months.

Sadly, a number of *Lernaea* have already become resistant against the available drugs.

For serious infections with Carp Lice or Anchorworms, it is advisable to disinfect the pond (or tank) (ask your pond retailer or veterinarian for advice)



584 • *Carassius auratus* 'Goldfish'

Parasitic infection: Goldfish with Anchorworm (*Lernaea*) at base of dorsal fin with red wound (Bacterial infection).

7. OTHER PROBLEMS: (Ill. 585-603)

a. FOOD-related problems:

When using the wrong food the fish will become weak and more prone to diseases.

NOT recommended: feeding the fish with floating sticks or flakes as these contain more air than food and have only a limited nutritional value. In addition, the waste of this type of food will rapidly contaminate the water.

Too many mosquito larvae pose a greater risk:

FishMycobacterium. Live fish food can introduce parasites into your pond.

Too much food can cause severe damage (both to the fish and to the pond environment).



Tip: Many of our beautiful fish unnecessarily die as a result of overfeeding or being given the wrong kind of food.

Recommended: use of high-quality, high-energy food containing sufficient proteins and digestible (non-animal) fats, with ingredients that are digested well and as such supply wholesome nutritional substances, at the same time producing only a limited amount of waste for the water.

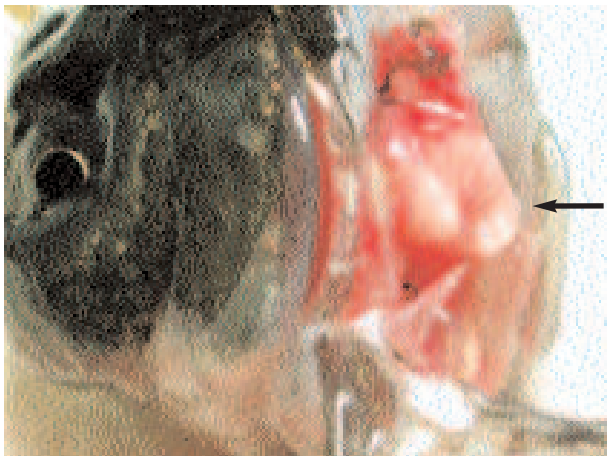The best food consists of fish + vegetable substances + vitamins. Preferably use dry food (pellets) of different size (depending on size of the fish), that sink and do not disintegrate. Pond fish prefer to eat off the bottom.

Pond fish eat very little in winter. This should be taken into account during feeding.

Goldfish and Koi can easily eat pellets with their masticating teeth (Ill. 585).

We recommend high-quality food (tip: do not save on quality) such as **Dr. Bassleer's Biofish Food**.

In the spring, with its temperature changes, the fish suffer



585 • *Carassius 'Oranda'*

Nutrition: Dissected head of Oranda with 2 large white 'fish teeth' which can grind food pellets.

from stress and Dr. Bassleer's Biofish Food FORTE can be used to build up resistance in your pond fish.

For further information consult your pond or aquarium shop (also: www.aquarium-munster.com).

b. SWIMMING UPSIDE DOWN

(= SWIM BLADDER problems) (Ill. 586-588)


= Typical for certain species of Ornamental Goldfish

The special and sometimes abnormal body shapes of Chinese Ornamental Goldfish (especially breeding specimens with short bodies) result in deformed bodies that make it difficult for the fish to regulate the intake and discharge of air at the swim bladder.



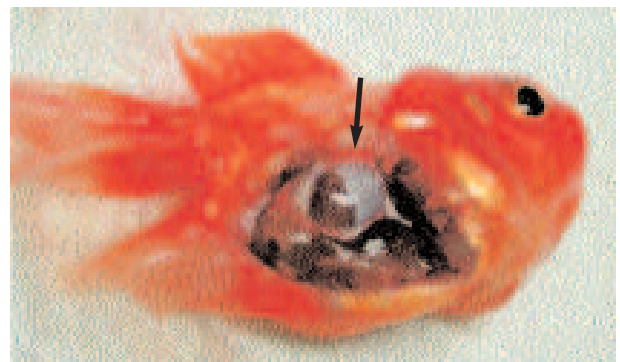
586 • *Carassius 'Oranda'*

Deformity: Oranda swimming upside down caused by Deformity of the swim bladder.



587 • *Carassius 'Oranda'*

Deformity: Oranda (see ill. 586) after dissection: swim bladder hidden behind the organs.



588 • *Carassius 'Oranda'*

Deformity: Oranda (see ill. 586) after removal of gonad: swim bladder is much enlarged + deformed.

The fish then risks losing its balance, it hangs at the surface and often swims on its back. Conclusion: a bent or too short back – a deformity produced in special breeding specimens – is the cause of this malfunctioning swim bladder.

This problem can also occur with bacterial (see *Aeromonas* infection) or parasitic infections, or in case of stress (shock) or damage.

TREATMENT: Some say that keeping the problem fishes in a 5% salt solution for 2 to 3 days solves the problem. Others have obtained good results by feeding cooked peas.

In the US, there is even a veterinarian who has specialised in the implantation of stones to help the fish keep its balance.

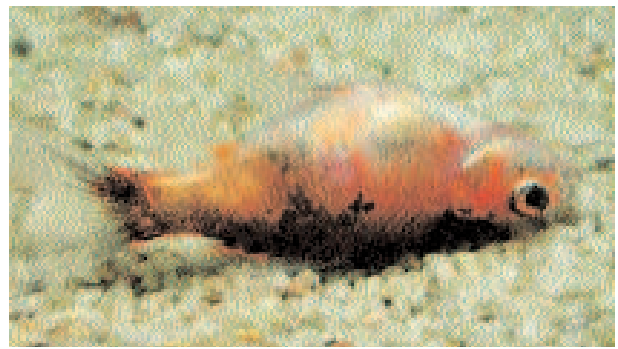
Our advice: prevention is better than cure (i.e., do not buy).

c. DEFORMITIES: (Ill. 589-602)

We have mainly come across lumps (usually Tumours) on the skin, liver, kidneys and sexual organs in adult fish. Some (especially those on the skin) can be surgically removed by a professional.

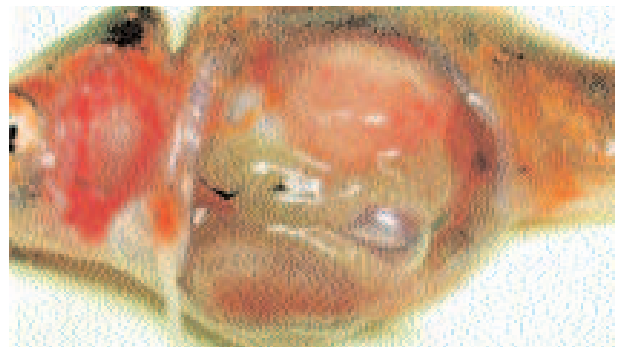
Fish with internal tumours can be operated on by a specialist but there is only a 30% survival rate.

A number of photos from Dr. Lammens' practice have been included for illustration purposes.



591 • *Carassius auratus* 'Shubunkin'

Deformity + Bacterial inf.: Shubunkin with swollen abdomen caused by tumour in kidney (also red patch caused by Bacterial inf.).



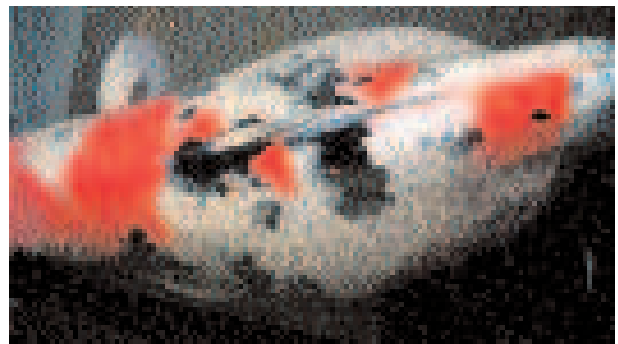
592 • *Carassius auratus* 'Shubunkin'

Deformity: Shubunkin (see ill. 591) after dissection: tumour in kidney pushing aside swim bladder and organs.



589 • *Carassius* 'Oranda Fantail'

Deformity: Fullgrown Fantail Goldfish with large, red swelling (tumour) on the body.



593 • *Cyprinus carpio* 'Koi Sanke'

Deformity: Adult Koi 'Shiro Utsuri': swollen abdomen caused by tumour. (Photo M. Lammens)




590 • *Carassius* 'Oranda Calico'

Deformity: Adult Oranda with a gigantic tumour. (Photo M. Lammens)

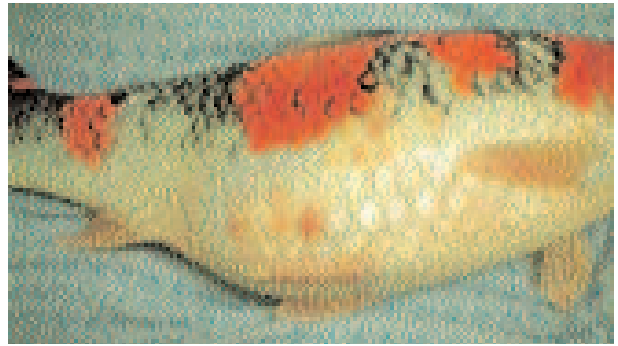

594 • *Cyprinus carpio* 'Koi Sanke'


Deformity: Dissected Koi 'Shiro Utsuri' with a large tumour in the gonads. (Photo M.Lammens)



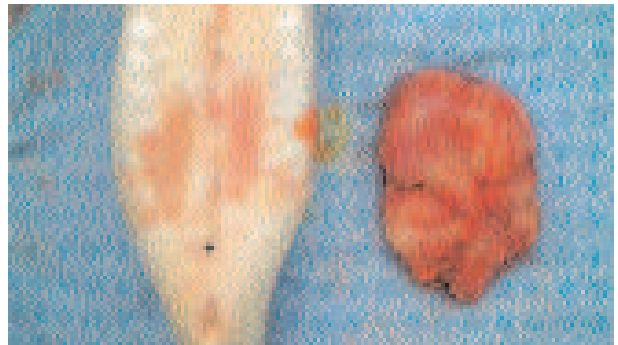
595 • *Cyprinus carpio* 'Koi Goshiki'
 Deformity: Koi 'Goshiki' with swollen abdomen caused by tumour (Photo M. Lammens)




596 • *Cyprinus carpio* 'Koi Goshiki'
 Deformity + Bacterial inf.: Koi 'Goshiki' (ill. 595) swollen abdomen + bloody scales (Bacterial inf.). (Photo M. Lammens)



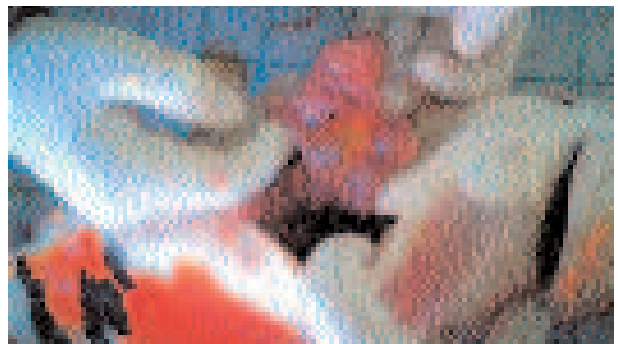597 • *Cyprinus carpio* 'Koi Goshiki'
 Treatment: Koi 'Goshiki' (ill. 596) treatment through (IM)injection with antibiotic (Florfenicol). (Photo M. Lammens)




598 • *Cyprinus carpio* 'Koi Goshiki'
 Treatment: Koi 'Goshiki' (ill. 595) after surgery and removal of tumour in the gonad. (Photo M. Lammens)




599 • *Cyprinus carpio* 'Koi Sanke'
 Deformity: Koi 'Sanke' with largely extended abdomen at one side caused by tumour. (Photo. M. Lammens)



600 • *Cyprinus carpio* 'Koi Sanke'
 Treatment: Koi 'Sanke' during surgery with tumour in the gonads. (Photo M. Lammens)



601 • *Cyprinus carpio* 'Koi Sanke'
 Treatment: Finishing and repairing Koi 'Sanke' after surgery and removal of tumour. (Photo M. Lammens)



602 • *Cyprinus carpio* 'Koi Sanke'
 Treatment: Koi 'Sanke' swimming well after surgery. (Photo M. Lammens)

D. LACK OF OXYGEN: (ILL. 603)

Ponds (but also aquariums) with Goldfish or Koi often do not have enough Oxygen. As a result, the fish have breathing difficulties, gasp for air and hang at the surface. This phenomenon is typically encountered in the summer (or when the water temperature exceeds 20°C) or in case of overcrowding.

Also a properly functioning biological filter consumes oxygen and the more fish we feed the more oxygen has to be consumed by the filter.

At night the plants consume oxygen and release CO₂.

Too many plants in the pond may thus leave the fish gasping for air at night and thus kill them.

Lack of oxygen causes stress and weakens the fish, so that a bacterial and/or parasitic infection can break out.

TREATMENT: A simple test with an oxygen meter would prevent a lot of problems.

The two common causes are overcrowding and overfeeding.

When it is particularly hot in summer, a water change and an additional air pump or circulating pump may prove necessary.

THANKS TO: Dr. Maarten Lammers for the professional photographic material on the Koi.

REFERENCE (+ LITERATURE):

- Dr. Maarten Lammers/Fish Doctor (active in Belgium, The Netherlands and Germany) Mobile (+32) (0)476202591
- Dawes (1998): The Pond Owner's Handbook. Ward Lock, England
- Dawes (2001): Het complete vijverboek, Tirion, The Netherlands
- Lechleiter&Kleingeld (2000): Krankheiten der Koi, Ulmer/Germany
- Noga (2000): Fish Disease, Iowa State University Press/USA
- Terwagne, Bastin & Jacobs (2001): Réussir son étang de jardin, Exotic 2000/Belgium
- www.koivet.com by Dr. Erik Johnson: specialist in Koi diseases
- www.fishdoc.co.uk Detailed information on fish diseases, with video images of microscopic recordings.
- www.pondlibrary.com = a Flemish website on Koi, interesting articles and lots of information



603 • Oxygen meter

Treatment: Oxygen meter: an indispensable tool to control water quality in ponds. (Photo M. Lammers)